

Histopathological evaluation of zebrafish (*Danio rerio*) larvae following embryonic exposure to MgO nanoparticles

Ghobadian M.^{1*}; Nabiuni M.¹; Parivar K.¹; Fathi M.², Pazooki J.³

Received: September 2015

Accepted: February 2016

Abstract

The aim of this study was to investigate the histopathological changes in zebrafish larvae following embryonic exposure to nanoparticles of magnesium oxide (MgONPs). The toxicity of metal oxide nanoparticles is attracting increasing attention. Among these nanomaterials, MgONPs are particularly interesting as a low cost and environmentally-friendly material. Histological investigations are used as a highly sensitive method for detecting the morphological features of disease and abnormal gene function. We evaluated the histopathological changes in zebrafish larval tissues following embryonic exposure to MgONPs for a period of 4-96 h post fertilization (hpf). To this end; fixation, tissue processing, sectioning and general staining of the whole-larvae were performed. Histopathological evaluations showed some changes including psoriasis-like epithelial hyperproliferation, muscle cell degeneration, neurodegeneration in the spinal cord, swelling and edematous changes in pericardium, swelling and edematous changes in yolk sac, severe edema within the eyes, smaller retina, disruption of retinal lamination and impaired retinal differentiation. In summary, the results of this study enhance our understanding about the potential hazards of MgONPs to the environment.

Keywords: Zebrafish, MgO nanoparticles, Histopathology, Embryo

1- Department of Developmental Biology, Faculty of Biological Sciences, Kharazmi University, Tehran, Iran.

2- Department of Biochemistry, Zanjan University of Medical Sciences, Zanjan, Iran.

3- Department of Marine Biology, Faculty of Biological Sciences, Shahid Beheshti University, Tehran, Iran.

*Corresponding author's Email: m54biology@yahoo.com

Introduction

Nanoparticles (NPs) have at least one dimension of 100 nm or less. The NPs have always existed in our environment, from both natural and anthropogenic sources (Thomas *et al.*, 2014). Among these NPs, Magnesium oxide NPs (MgONPs) are particularly interesting because of their wide applications in various areas such as industry, medicine and food stuff (Guo *et al.*, 1996; Poullikkas *et al.*, 2004 ; Shi *et al.*, 2010; Krishnamoorthy *et al.*, 2012). Since the final destination of manufactured nanomaterials is aquatic ecosystems, and these materials are likely to have adverse effects on aquatic organisms, the evaluation of their potential toxicity effects is very important. Zebrafish is one of the model organisms most commonly used in toxicity tests (Lele and Krone, 1996). Also histological investigation is a highly sensitive method for detecting the morphological features of disease and abnormal gene function. Histology has been accepted as a phenotyping method for the zebrafish phenome project (Canada *et al.*, 2010). Nanoparticles can be absorbed through the skin, lungs and the digestive system (Buzea *et al.*, 2007). Upon exposure to NPs, ROS generation induces oxidative DNA damage, protein denaturation and lipid peroxidation demonstrating the mutagenic and carcinogenic properties of nanoparticles (Manke *et al.*, 2013). Studies have shown that cellular apoptosis and intracellular reactive oxygen species (ROS) are the main

mechanisms of MgONPs toxicity (Krishnamoorthy *et al.*, 2012; Yu *et al.*, 2013 and Ghobadian *et al.*, 2015).

Some studies have investigated histological changes in fish models following exposure to different materials. Naeemi *et al.* (2013) evaluated histopathological changes of gill, liver and kidney in Caspian kutum exposed to Linear Alkylbenzene Sulfonate. The results showed that sublethal concentrations of Linear Alkylbenzene Sulfonate may affect sever changes to gill, Kidney and liver. Fuat Gulhan *et al.* (2014) investigated the effects of propolis on gill, liver and muscle tissues of rainbow trout exposed to various concentrations of cypermethrin (CYP). Shorting the secondary lamellae, fusion of secondary lamellae, oedema, necrosis, vacuolization and cartilage damage in gill tissue of fish exposed to CYP were observed by histopathological analyses. Hepatic lesions in liver tissue of fish exposed to CYP were characterized as hydropic degeneration, necrosis, mononuclear cell infiltration and narrowing of sinusoids. The most common changes in muscle tissues at all concentrations of CYP were nuclear proliferation and congestion. Wu *et al.* (2010) evaluated the effects of silver nanoparticles on the development and histopathology biomarkers of Japanese Medaka (*Oryzias latipes*). Morphological abnormalities in early-life stages of Medaka showed the potential developmental toxicity of silver nanoparticles. Mansouri *et al.*

(2015) evaluated the effects of nanoparticles of cobalt oxide and cobalt ions on gill histopathology of zebrafish (*Danio rerio*). The results showed several gill injuries such as aneurism, dilated and clubbed tips, hyperplasia, oedema, curvature, fusion of lamellae, increase of mucous secretion, hypertrophy, and necrosis. Subashkumar and Selvanayagam (2014) showed that nanoparticles of zinc oxide cause gill histopathological damages in *Cyprinus carpio*. Griffitt *et al.* (2007) revealed that exposure to copper nanoparticles causes gill injury and acute lethality in zebrafish (*D. rerio*). Histological and biochemical analysis showed that the gill was the primary target organ for nanocopper. Based on our previous study; the 96-h LC50 value of MgONPs on the zebrafish survival was 428 mgL⁻¹ (Ghobadian *et al.*, 2015). To our best knowledge this is an initial investigation of histological changes in embryonic tissues of zebrafish larvae following embryonic exposure to MgONPs sized 20 nm for 4-96 hpf.

Materials and methods

MgONPs preparation and characterization

The nanoparticles used in this study were the same particles that had been used in our previous study (Ghobadian *et al.*, 2015). In brief uncoated MgONPs of size 20 nm with a polyhedral morphology and 98% purity were purchased from US Research Nanomaterials (CAS#1309-48-4).

Scanning electron microscopy studies in our previous work confirmed the polyhedral shape and size 20 nm of MgONPs (Ghobadian *et al.*, 2015). MgONPs (50, 100, 200 and 400 mgL⁻¹) were prepared in zebrafish culture medium consisting of 64.75 mgL NaHCO₃, 5.75 mgL⁻¹ KCl, 123.25 mgL⁻¹ MgSO₄.7H₂O and 204 mgL⁻¹ CaCl₂.2H₂O [International Standard Organization (ISO), 1996]. The zeta potentials of the MgONPs in culture medium were determined using a DLS device (Malvern Nano-Zs; Britain).

Zebrafish culture, breeding and embryo selection

The detailed procedure for zebrafish culture, breeding and embryo selection is provided in our previous paper (Ghobadian *et al.*, 2015). In brief, zebrafish adults with a 2:1 male/female sex ratio were kept in an 80-L aquarium at 26°C. The animals were fed with brine shrimp daily. The photoperiod was adjusted to a 14-h/10-h light/dark cycle. After spawning, that was triggered in the morning; the embryos were collected, washed with culture medium and controlled under a light microscope (Olympus; Japan). Healthy embryos were then separated for the exposure process.

Exposure process

For the exposure process, fertilized embryos were placed in 24-well culture plates (10 embryos in 2 mL solution per well). The embryos were treated with MgONPs (50, 100, 200 and 400 mgL⁻¹)

and a control of culture medium for 4-6 hours post-fertilization (hpf). Each group had 3 replicate wells and each experiment was repeated 3 times. The wells of the culture plates were covered with transparent plastic films to maintain a constant concentration. We confirm that all studies were performed according to the guidelines of the IACUC.

Histopathology

The fish (15 larvae from each concentration) were selected for histological examination, fixed in buffered 10% formalin, dehydrated, cleared, embedded in paraffin wax, sectioned on a microtome at a thickness of 5 μm and stained with Haematoxylin and Eosin (Plhalova *et al.*, 2012).

Approximately 10 slides were produced from each larva for microscopic analysis. Histopathological changes such as hyperproliferation, edema, degeneration and other possible morphological changes were evaluated compared to the control group.

Histopathological scoring

Histopathological scoring was performed on all serial sections according to Zodrow *et al.* (2004). Histopathology was determined based on severity of changes in treatment groups compared to control group sections. Score determination was based on the severity as well as the number of slides out of the total in which the histological changes were observed with minus (-) =no histopathology; plus

(+) =histopathology in <25% of fields (mild); (++) =histopathology in>75% of fields (moderate); (++++)= histopathology in all fields (severe).

Results

In Fig. 1 the scanning electron microscope (SEM) image of MgONPs is shown. The zeta potential for 50, 100, 200 and 400 mgL^{-1} solutions of MgONPs in zebrafish culture medium was -11.21, 2.93, 15.12 and 24.4, respectively.

The fish were exposed to 4 sublethal concentrations of MgONPs. Histopathological examinations revealed pathological changes only in MgONPs exposed groups. All affected tissues in zebrafish larvae were compared with tissue sections of control group. The results of whole-larva histopathological investigations after 4-96 hpf exposure to MgONPs are shown in Fig. 2.

Swelling and edematous changes in pericardium (Tsuruwaka *et al.*, 2015) and yolk sac (Haas *et al.*, 2011) were the most common histopathological changes that were observed in sections of all treated groups (Table 1).

Morphological changes confirming the muscle cell degeneration (Schmid *et al.*, 2013) and neurodegeneration (Faria *et al.*, 2015; Yanwei *et al.*, 2011) in the spinal cord were observed in zebrafish embryos exposed to MgONPs. Microscopic examinations of the epidermis, showed psoriasis-like epithelial hyperproliferation (Dodd *et al.*, 2009) in zebrafish embryos exposed to MgONPs.




Figure 1: The scanning electron microscope (SEM) image of MgONPs (Direct Mag: 200000×).

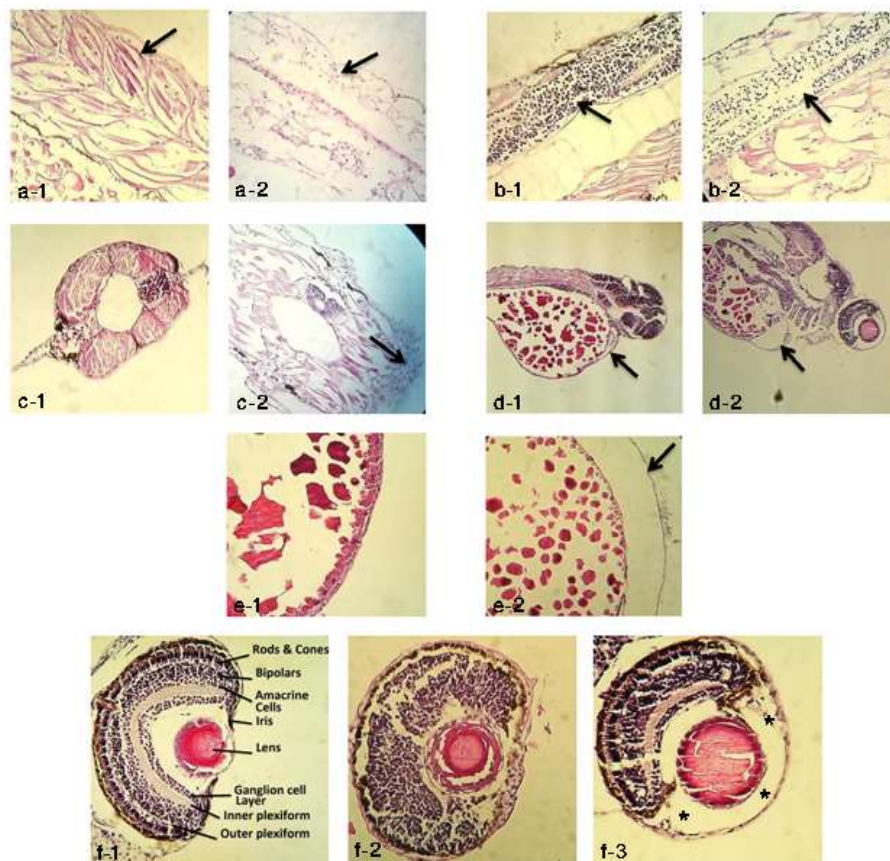


Figure 2: Histopathology of zebrafish embryos exposed to MgONPs (50, 100, 200, and 400 mg/L).

a-1, Trunk muscle from control group (arrow), a-2, Trunk muscle of MgONPs exposed zebrafish embryos displaying muscle cell degeneration (arrow) (100×); b-1, Spinal cord from control group (arrow), b-2, Spinal cord of MgONPs exposed zebrafish embryos displaying neurodegeneration (arrow) (100×); c-1, Tail cross section from control group, c-2, Tail cross section of MgONPs exposed zebrafish embryos displaying Psoriasis-like epithelial hyperproliferation (arrow) (100×); d-1, Longitudinal section from control group displaying normal pericardium (arrow), d-2, Longitudinal section of MgONPs exposed zebrafish embryos displaying swelling and edematous changes in pericardium (arrow) (40×); e-1, Longitudinal section from control group displaying normal yolk sac, e-2, Longitudinal section of MgONPs exposed zebrafish embryos displaying swelling and edematous changes in yolk sac (arrow) (100×); f-1, Eye cross section with retinal layers from control group, f-2, Eye cross section of MgONPs exposed zebrafish embryos displaying impaired retinal differentiation and disruption of retinal lamination, f-3, Eye cross section of MgONPs exposed zebrafish embryos displaying smaller retina and sever edema within the eye (asterisks) (100×).

Also histological analysis showed severe edema within the eyes (Weiss *et al.*, 2012), smaller retina (Seipold *et al.*, 2009), disruption of retinal lamination

(Wei *et al.*, 2004) and impaired retinal differentiation (Biehlmaier *et al.*, 2007) (Table 1).

Table 1: Histopathological analysis of MgONPs exposed zebrafish embryos and control group.

Pathology	Control	MgONPs Concentration (mgL ⁻¹)			
		50	100	200	400
Muscle cell degeneration	-	-	+	++	+++
Neurodegeneration in the spinal cord	-	-	+	+	+++
Psoriasis-like epithelial hyperproliferation	-	-	+	+	+
Swelling and edematous changes in pericardium	-	+++	+++	+++	+++
Swelling and edematous changes in yolk sac	-	+++	+++	+++	+++
Sever edema within the eyes	-	-	-	+++	+++
Smaller retina	-	-	-	-	+++
Disruption of retinal lamination	-	-	-	+++	+++
Impaired retinal differentiation	-	-	-	+++	+++

Discussion

MgONPs have been employed in various areas such as medicine, industry and in food stuff (Guo *et al.*, 1996; Poullikkas *et al.*, 2004; Shi *et al.*, 2010; Krishnamoorthy *et al.*, 2012), leading to their increased organism exposure, thereby posing potential health hazards to humans and other organisms. Testing was conducted on zebrafish embryos as an *in vivo* vertebrate model organism. The objective of this study was to investigate the histopathological changes in zebrafish larval tissues following embryonic exposure to MgONPs for 4-96 hpf. Size 20 nm and polyhedral morphology of the MgONPs were confirmed by scanning electron microscope in our previous study (Ghobadian *et al.*, 2015). Small changes in zeta potentials of the MgONPs in culture medium were observed compared to our previous study (Ghobadian *et al.*, 2015). This could be due to differences in measurement

conditions or devices sensitivity. Nanoparticles can enter cells and interact with subcellular structures (Buzea *et al.*, 2007). It has been observed that NPs may trigger oxidative stress, inflammation, and indirect DNA damage in living systems (Sabella *et al.*, 2014). Some studies have shown that the toxicity of MgONPs has been attributed to ROS production (Yu *et al.*, 2013; Ghobadian *et al.*, 2015). ROS generation can cause oxidative DNA damage, and protein denaturation (Manke *et al.*, 2013). Also other studies have shown that cellular apoptosis is the other mechanism of toxicity caused by MgONPs (Krishnamoorthy *et al.*, 2012; Ghobadian *et al.*, 2015). Given the toxicity mechanisms caused by MgONPs and mutagenic properties of nanoparticles (Manke *et al.*, 2013), it can be expected that after arrival into the cells, MgONPs will be able to interfere with the process of embryonic development and affect various organs

and tissues. In this study, histopathological evaluations showed some changes in different organs and tissues including Psoriasis-like epithelial hyperproliferation, muscle cell degeneration, neurodegeneration in the spinal cord, swelling and edematous changes in pericardium, swelling and edematous changes in yolk sac, sever edema within the eyes, smaller retina, disruption of retinal lamination and impaired retinal differentiation.

Histopathological evaluation of zebrafish larvae tissue sections showed a high degree of muscle cell degeneration compared to the control group (Fig. 2. a-1, a-2). Some studies have described the apoptosis role in some structures such as the notochord, somites and muscle in a zebrafish model (Cole and Ross, 2001). Therefore, it can be concluded that widespread muscle degeneration observed in the zebrafish larvae following embryonic exposure to MgONPs may be related to the presence of apoptosis in muscle cells and emphasize on the toxicity properties of these nanoparticles.

Also, there was a significant reduction in the number of neurons in the spinal cord in the treated group tissue sections compared to the control group (Fig 2. b-1, b-2). The relationship between neurodegeneration in zebrafish embryos and gene malfunction has been demonstrated (Yanwei *et al.*, 2011). Also given the role of apoptosis in neurodegenerative diseases (Mattson, 2000; Robert and Friedlander, 2003)

and the proven role of apoptosis in the toxicity of MgONPs (Krishnamoorthy *et al.*, 2012; Ghobadian *et al.*, 2015), it can be concluded that significant reduction observed in the number of neurons in the spinal cord of the zebrafish larvae following embryonic exposure to MgONPs, may be related to the apoptosis present in neural cells of the spinal cord.

The zebrafish epidermis envelopes the embryo by 14 hpf and provides a barrier between the internal organs and external environment. As the zebrafish embryo increases in size, keratinocytes must proliferate and differentiate to form the three epidermal layers (Webb *et al.*, 2008). Dodd *et al.* (2009) have been described a mutant that exhibits psoriasis-like phenotypes including epithelial hyperproliferation. Our findings in histopathological examinations of the tissue sections, revealed clear signs of epithelial cells hyperproliferation in the tail region of the treated groups (Fig. 2. c-1, c-2). The presence of psoriasis-like epithelial hyperproliferation in zebrafish larvae following embryonic exposure to MgONPs, confirms the toxicity effects of these nanoparticles on zebrafish embryos.

In the histopathological study of the pericardial region, there was a clear swelling and edematous changes in pericardium of the treated groups and pericardial cavity was obviously enlarged (Fig. 2. d-1, d-2). Given the proven role of genetic defects in the occurrence of edematous changes in

pericardium (Tsuruwaka *et al.*, 2015), it can be concluded that the presence of this histopathological changes in the zebrafish larvae tissue sections following embryonic exposure to MgONPs is due to toxic properties of these nanoparticles.

Also, histopathological examinations, showed obvious swelling and edematous changes in yolk sac of treated larvae compared to the control group (Fig. 2. e-1, e-2). Given the proven role of genetic defects in the occurrence of edematous changes in yolk sac (Haas *et al.*, 2011), it can be concluded that the presence of these histopathological changes in the treated group tissue sections is due to the toxic effects of MgONPs. Swelling and edematous changes in pericardium and yolk sac were the most common defects that were observed in the tissue sections of all treated groups. Histopathological findings of this study about swelling and edematous changes in pericardium and yolk sac, confirm our results in previous study (Ghobadian *et al.*, 2015).

Histopathological evaluation of the eyes in treated groups showed some degree of tissue damage that was associated with the incomplete development of this organ (Fig. 2. f-1, f-2, f-3). The results showed some defects including severe edema within the eyes, smaller retina, disruption of retinal lamination and impaired retinal differentiation. Various studies have demonstrated the role of genes in zebrafish eye development (Fadool and Dowling, 2008). In this

study, the presence of these defects in the eye structure is considered to be due to the toxic effects of MgONPs in Zebrafish embryos which interfere with the normal development of this organ.

Based on histological investigations, there were not certain pathological changes in other organs and tissues.

Overall, our findings showed that MgONPs cause various changes in different organs and tissues of zebrafish larvae following embryonic exposure to them (4-96 hpf). Also this study confirms our previous results about MgONPs toxicity effects and enhances our understanding about their potential hazards to the environment.

References

- Biehlmaier, O., Makhankov, Y. and Neuhauss, S.C., 2007.** Impaired retinal differentiation and maintenance in zebrafish laminin mutants. *Investigative Ophthalmology and Visual Science*, 48(6), 2887-94.
- Buzea, C., Pacheco Blandino, I.I., Robbie, K., 2007.** Nanomaterials and nanoparticles: sources and toxicity. *Biointerphases*, 2, 1-103.
- Canada, B.A., Thomas, G.K., Cheng, K.C. and Wang, J.Z., 2011.** SHIRAZ: an automated histology image annotation system for zebrafish phenomics. *Multimedia Tools and Applications*, 51(2), 401-440.
- Cole, L.K. and Ross L.S., 2001.** Apoptosis in the developing

- zebrafish embryo. *Developmental biology*, 240, 123-142.
- Dodd, M.E., Hatzold, J., Mathias, J.R., Walters, K.B., Bennin, D.A., Rhodes, J., P. Kanki, J., Look, A.T., Hammerschmidt, M., and Huttenlocher, A., 2009.** The ENTH domain protein clint1 is required for epidermal homeostasis in zebrafish. *Development*, 136, 2591-2600.
- Fadool, J.M. and Dowling, J.E., 2008.** Zebrafish: A model system for the study of eye genetics. *Progress in Retinal and Eye Research*, 27, 89–110.
- Faria, M., Garcia-Reyero, N., Padrós, F., Babin, P.J., Sebastián, D., Cachot, J., Prats, E., Arick II, M., Rial, E., Knoll-Gellida, A., Mathieu, G., Le Bihanic, F., Escalon, B.L., Zorzano, A., Soares, A.M.V.M. and Raldua, D., 2015.** Zebrafish Models for Human Acute Organophosphorus Poisoning. *Scientific Reports*, 5, 15591.
- Fuat Gulhan, M., Selamoglu Talas, Z., Erdogan, K. and Orun, I., 2014.** The effects of propolis on gill, liver, muscle tissues of rainbow trout (*Oncorhynchus mykiss*) exposed to various concentrations of cypermethrin. *Iranian Journal of Fisheries Sciences*, 13(3), 684-701.
- Ghobadian, M., Nabiuni, M., Parivar, K., Fathi, M. and Pazooki, J., 2015.** Toxic effects of magnesium oxide nanoparticles on early developmental and larval stages of zebrafish (*Danio rerio*). *Ecotoxicology and Environmental Safety*. Doi: 10.1016/j.ecoenv.
- Griffitt, R.J., Weil, R., Hyndman, K.A., Denslow, N.D., Powers, K., Taylor, D. and Barber, D.S., 2007.** Exposure to copper nanoparticles causes gill injury and acute lethality in zebrafish (*Danio rerio*). *Environmental Science and Technology*, 41(23), 8178–8186.
- Guo, X.L., Liu, Z.G., Chen, X.Y., Zhu, S.N., Xiong, S.B., Hu, W.S. and Lin, C.Y., 1996.** Pulsed laser deposition of SrxBal-xNb2O6/MgO bilayered films on Si wafer in waveguide form. *Journal of Physics D*. 29, 1632.
- Haas, U., Raschperger, E., Hamberg, M., Samuelssona, B., Tryggvason, K. and Haeggström, J.Z., 2011.** Targeted knock-down of a structurally atypical zebrafish 12S-lipoxygenase leads to severe impairment of embryonic development. *PNAS*, 51, 20479–20484.
- International standard organization (ISO), 1996.** Water quality-determination of the acute lethal toxicity of substances to a freshwater fish [Brachydanio rerio Hamilton-Buchanan (Teleostei, Cyprinidae)]-Part 3: Flow-through method. ISO 7346-3. Geneva, Switzerland.
- Krishnamoorthy, K., Jeong, Y.M., Ho, B.H., Somi, K.C. and Sang, J.K., 2012.** Mechanistic investigation on the toxicity of MgO nanoparticles toward cancer cells. *Journal of Materials Chemistry*, 22, 24610-24617.

- Lele, Z. and Krone, P.H., 1996.** The zebrafish as a model system in developmental toxicological and transgenic research. *Biotechnology Advances*, 14, 57-72.
- Manke, A., wang, L. and Yon, R., 2013.** Mechanisms of nanoparticle induced oxidative stress and toxicity. *BioMed Research International*, 2013, 1-15.
- Mansouri, B., Maleki, A., Johari, S.A. and Reshahmanish, N., 2015.** Effects of cobalt oxide nanoparticles and cobalt ions on gill histopathology of zebrafish (*Danio rerio*). *Aquaculture, Aquarium, Conservation and Legislation (AACL) Bioflux*, 8(3), 438-444.
- Mattson, M. P., 2000.** Apoptosis in neurodegenerative disorders. *Nature Reviews Molecular Cell Biology*, 1, 120-130.
- Naeemi, A., Jamili, S., Shabanipour, N., Mashinchian, A. and Shariati Feizabadi, S., 2013.** *Iranian Journal of Fisheries Sciences*. 12(4) 887-897.
- Phalova, L., Blahova, J., Mikulikova, I., Stepanova, S., Dolezelova, P., Praskova, E., Marsalek, P., Skoric, M., Pistekova, V., Bedanova, I. and Svobodova, Z., 2012.** Effects of subchronic exposure to atrazine on zebrafish (*Danio rerio*). *Polish Journal of Veterinary Sciences*, 15, 417-423.
- Poullikkas, A., 2004.** Coast-benefit analysis for the use of additives in heavy fuel oil fired boilers. *Energy Conversion Management*, 45, 1725-1734.
- Robert, M. and Friedlander, M.D., 2003.** Apoptosis and caspases in neurodegenerative diseases. *The New England Journal of Medicine*, 348, 1365-1375.
- Sabella, S., Carney, R.P., Brunetti, V., Malvindi, M.A., Al-Juffali, N., Vecchio, G., Janes, S.M., Bakr, O.M., Cingolani, R., Stellacci, F. and Pompa, P.P., 2014.** A general mechanism for intracellular toxicity of metal-containing nanoparticles. *Nanoscale*, 6, 7052.
- Schmid, B., Hruscha, A., Hogl, S., Banzhaf-Strathmann, J., Strecker, K., Van der Zee, J., Teucke, M., Eimer, S., Hegermann, J., Kittelmann, M., Kremmer, E., Cruets, M., Solchenberger, B., Hasenkamp, L., Van Bebber, F., Van Broeckhoven, C., Edbauer, D., F. Lichtenthaler, S. and Haass, C., 2013.** Loss of ALS-associated TDP-43 in zebrafish causes muscle degeneration, vascular dysfunction, and reduced motor neuron axon outgrowth. *PNAS*, 110, 4986-4991.
- Seipold, S., Priller, F.C., Goldsmith, P., Harris, W.A., Baier, H. and Abdelilah-Seyfried, S., 2009.** Non-SMC condensin I complex proteins control chromosome segregation and survival of proliferating cells in the zebrafish neural retina. *BMC Developmental Biology*, 9, 40.
- Shi, L.E., Xing, L., Hou, B., Ge, H., Guo, X. and Tang, Z., 2010.** Inorganic nano metal oxides used as anti-microorganism agents for

- pathogen control. *Microbial Biotechnology*, 1, 361-368.
- Subashkumar, S. and Selvanayagam, M., 2014.** First report on: Acute toxicity and gill histopathology of fresh water fish *Cyprinus carpio* exposed to Zinc oxide (ZnO) nanoparticles. *International Journal of Scientific and Research Publications*, 4, 1-4.
- Thomas, J., Vijayakumar, S., Thanigaivel, S., Mukherjee, A., Chandrasekaran, N., 2014.** Toxicity of magnesium oxide nanoparticles in two fresh water fishes tilapia (*Oreochromis mossambicus*) and zebrafish (*Danio rerio*). *International Journal of Pharmacy and Pharmaceutical Sciences*, 6, 487- 490.
- Tsuruwaka, Y., Konishi, M. and Shimada, E., 2015.** Loss of wwox expression in zebrafish embryos causes edema and alters Ca²⁺ dynamics. *PeerJ*, 1-12.
- Webb, A.E., Driever, W. and Kimelman, D., 2008.** Psoriasis regulates epidermal development in zebrafish. *Developmental Dynamics*, 237, 1153–1164.
- Wei, X., Cheng, Y., Luo, Y., Shi, X., Nelson, S. and Hyde, D.R., 2004.** The zebrafish *pard3* ortholog is required for separation of the eye fields and retinal lamination. *Developmental Biology*, 269, 286–301.
- Weiss, O., Kaufman, R., Michaeli, N. and Inbal, A., 2012.** Abnormal vasculature interferes with optic fissure closure in lmo2 mutant zebrafish embryos. *Developmental Biology*, 369, 191–198.
- Wu, Y., Zhou, Q., Li, H., Liu, W., Wang, T. and Jiang, G., 2010.** Effects of silver nanoparticles on the development and histopathology biomarkers of Japanese medaka (*Oryzias latipes*) using the partial-life test. *Aquatic Toxicology*, 100(2), 160-7.
- Yanwei, X., Sandra, N. and Marc, E., 2011.** Modeling neurodegeneration in zebrafish. *Current Neurology and Neuroscience Reports*, 11, 274–282.
- Yu, H.L., Alan, M.C. Ng., Xiaoying, X., Zhiyong, S., Lee, A.G., Mable, T.W., Charis, M.N. C., Mu, Y.G., Yip, H.N., Aleksandra, B.D., Patrick, K.H.L., Wai, K.C., Li, H.Y., David, L.P., Angel, P.Y.M. and Frederick C.C.L., 2013.** Mechanisms of antibacterial activity of MgO: Non-ROS mediated toxicity of MgO nanoparticles towards *Escherichia coli*. *Small*, 10, 1171-1183.
- Zodrow, J.M., Stegeman, J.J. and Tanguay, R.L., 2004.** Histological analysis of acute toxicity of 2, 3, 7, 8-tetrachlorodibenzo-*p*-dioxin (TCDD) in Zebrafish. *Aquatic Toxicology*, 66, 25-38.